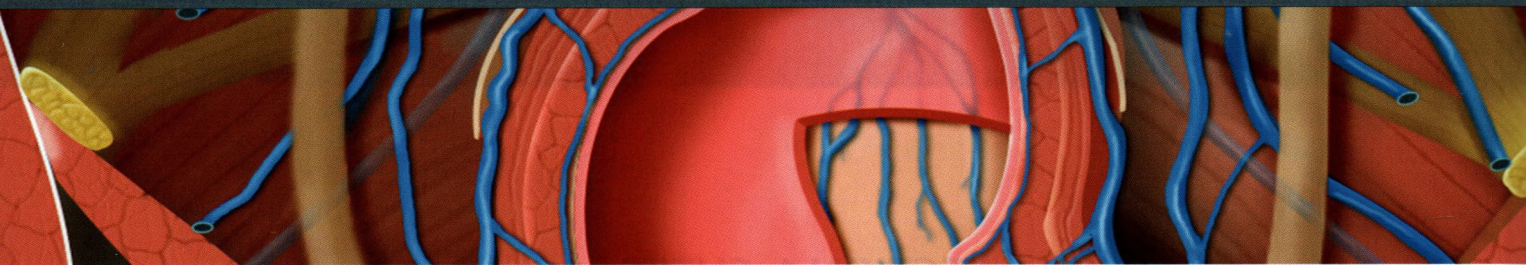


TABLE OF CONTENTS



SECTION 1: CHEST

- 4 Chest Overview**
Melissa L. Rosado-de-Christenson, MD, FACP
- 44 Lung Development**
Melissa L. Rosado-de-Christenson, MD, FACP
- 64 Airway Structure**
Brett W. Carter, MD and Gerald F. Abbott, MD, FACP
- 86 Vascular Structure**
Melissa L. Rosado-de-Christenson, MD, FACP
- 106 Interstitial Network**
Brett W. Carter, MD and Gerald F. Abbott, MD, FACP
- 118 Lungs**
Melissa L. Rosado-de-Christenson, MD, FACP
- 148 Hila**
Melissa L. Rosado-de-Christenson, MD, FACP
- 178 Airways**
Brett W. Carter, MD and Gerald F. Abbott, MD, FACP
- 200 Pulmonary Vessels**
Melissa L. Rosado-de-Christenson, MD, FACP
- 232 Pleura**
Brett W. Carter, MD and Gerald F. Abbott, MD, FACP
- 258 Mediastinum**
Melissa L. Rosado-de-Christenson, MD, FACP
- 294 Systemic Vessels**
Melissa L. Rosado-de-Christenson, MD, FACP
- 336 Heart**
Melissa L. Rosado-de-Christenson, MD, FACP
- 380 Coronary Arteries and Cardiac Veins**
Akram M. Shaaban, MBChB
- 402 Pericardium**
Melissa L. Rosado-de-Christenson, MD, FACP
- 422 Chest Wall**
Brett W. Carter, MD and Gerald F. Abbott, MD, FACP

SECTION 2: ABDOMEN

- 448 Embryology of Abdomen**
Michael P. Federle, MD, FACP and Siva P. Raman, MD
- 484 Abdominal Wall**
Siva P. Raman, MD and Michael P. Federle, MD, FACP
- 508 Diaphragm**
Siva P. Raman, MD and Michael P. Federle, MD, FACP
- 528 Peritoneal Cavity**
Siva P. Raman, MD and Michael P. Federle, MD, FACP
- 550 Vessels, Lymphatic System and Nerves, Abdominal**
Siva P. Raman, MD and Michael P. Federle, MD, FACP
- 592 Esophagus**
Michael P. Federle, MD, FACP and Siva P. Raman, MD
- 608 Gastroduodenal**
Siva P. Raman, MD and Michael P. Federle, MD, FACP

- 636 Small Intestine**
Siva P. Raman, MD and Michael P. Federle, MD, FACP
- 666 Colon**
Siva P. Raman, MD and Michael P. Federle, MD, FACP
- 708 Spleen**
Siva P. Raman, MD and Michael P. Federle, MD, FACP
- 732 Liver**
Siva P. Raman, MD and Michael P. Federle, MD, FACP
- 778 Biliary System**
Siva P. Raman, MD and Michael P. Federle, MD, FACP
- 804 Pancreas**
Siva P. Raman, MD and Michael P. Federle, MD, FACP
- 834 Retroperitoneum**
Siva P. Raman, MD and Michael P. Federle, MD, FACP
- 860 Adrenal**
Siva P. Raman, MD and Michael P. Federle, MD, FACP
- 882 Kidney**
Siva P. Raman, MD and Michael P. Federle, MD, FACP
- 920 Ureter and Bladder**
Siva P. Raman, MD and Michael P. Federle, MD, FACP

SECTION 3: PELVIS

- 946 Vessels, Lymphatic System and Nerves, Pelvic**
Paula J. Woodward, MD and Akram M. Shaaban, MBChB

MALE

- 974 Male Pelvic Wall and Floor**
Paula J. Woodward, MD and Akram M. Shaaban, MBChB
- 1000 Testes and Scrotum**
Paula J. Woodward, MD and Akram M. Shaaban, MBChB
- 1018 Prostate and Seminal Vesicles**
Paula J. Woodward, MD and Akram M. Shaaban, MBChB
- 1036 Penis and Urethra**
Paula J. Woodward, MD and Akram M. Shaaban, MBChB

FEMALE

- 1050 Female Pelvic Floor**
Paula J. Woodward, MD, Rania Farouk El Sayed, MD, PhD, and Akram M. Shaaban, MBChB
- 1078 Uterus**
Paula J. Woodward, MD and Akram M. Shaaban, MBChB
- 1104 Ovaries**
Paula J. Woodward, MD and Akram M. Shaaban, MBChB