

UNIT 1 Orofacial Structures

- 1 Face and Neck Regions, 1
- 2 Oral Cavity and Pharynx, 9

UNIT 2 Dental Embryology

- 3 Prenatal Development, 19
- 4 Face and Neck Development, 33
- 5 Orofacial Development, 44
- 6 Tooth Development and Eruption, 52

UNIT 3 Dental Histology

- 7 Cells, 79
- 8 Basic Tissue, 86
- 9 Oral Mucosa, 105
- 10 Gingival and Dentogingival Junctional Tissue, 124
- 11 Head and Neck Structures, 135
- 12 Enamel, 149
- 13 Dentin and Pulp, 160
- 14 Periodontium: Cementum, Alveolar Process, and Periodontal Ligament, 175

UNIT 4 Dental Anatomy

- 15 Overview of Dentitions, 197
- 16 Permanent Anterior Teeth, 211
- 17 Permanent Posterior Teeth, 231
- 18 Primary Dentition, 265
- 19 Temporomandibular Joint, 275
- 20 Occlusion, 285

Bibliography, 303

Glossary, 304

Appendix A: Anatomic Position, 315

Appendix B: Units of Measure, 316

Appendix C: Tooth Measurements, 317

Appendix D: Tooth Development, 319

Index, 321

3. Locate and identify the regions and associated surface landmarks of the neck on a diagram and a patient.
4. Integrate the clinical considerations for the surface anatomy of the face and neck into patient examination and care.

while referring to this textbook as well as the Workbook for Illustrated Dental Embryology, Histology, and Anatomy in order to improve your skills of examination. Later locating them on peers and then on patients in a clinical setting will add a real-world level of competence.

The regions of the face include the frontal, orbital, nasal, infraorbital, zygomatic, buccal, oral, and mental regions (Fig. 1.1). Lymph nodes (lunf) are located in certain areas of the face and head and when palpable should be noted in the patient record (Fig. 1.2, also see Fig. 1.15).

Frontal, Orbital, and Nasal Regions

The frontal region (frun-tal) of the face includes the forehead and the area above the eyes (Fig. 1.3). In the orbital region (awr-bi-tal) of the face, the eyeball and all its supporting structures are contained in the orbit (awr-bit) of the skull, which is the bony eye socket.

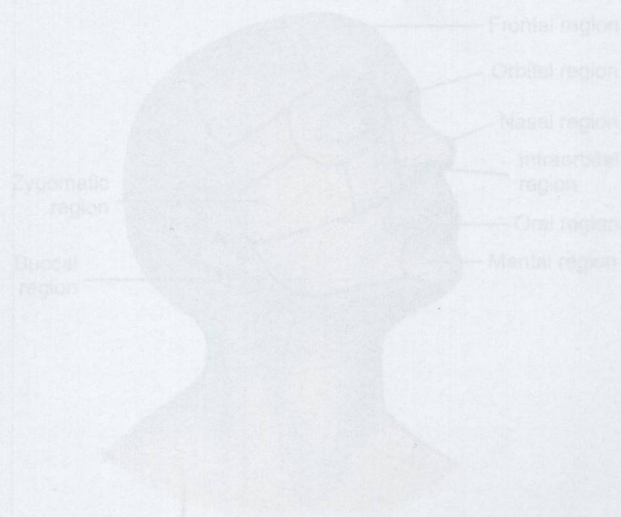


Fig. 1.1 Regions of the face include the frontal, orbital, infraorbital, nasal, zygomatic, buccal, oral, and mental. (Modified from Perry-Bachmann Hering, BV, *Illustrated Anatomy of the Head and Neck*, 5th ed., St. Louis: Elsevier, 2017.)