

# CONTENTS

## THE Laryngoscope

FOUNDED IN 1896

VOLUME 122 | NUMBER 2 | FEBRUARY 2012 | [www.laryngoscope.com](http://www.laryngoscope.com)


### EDITORIAL

- 243 **Sleep Medicine**  
*Michael G. Stewart, MD, MPH*

### TRIOTOLOGICAL SOCIETY BEST PRACTICE

- 244 **Endoscopic Versus Open Craniofacial Resection of Esthesioneuroblastoma: What is the Evidence?**  
*Zachary M. Soler, MD; Timothy L. Smith, MD, MPH*

### FACIAL PLASTICS/RECONSTRUCTIVE SURGERY

- 246 **Differential Management of Scaphocephaly**  
*Sherard A. Tatum, MD; Lamont R. Jones, MD; Minji Cho, MD; Ranjit Sandu, MD*
- 254 **Cosmetics and Function: Quality-of-Life Changes After Rhinoplasty Surgery**  
*Amy M. Saleh, MD; Ahmed Younes, MBChB, MSc; Oren Friedman, MD*
- 260 **Posterior Pharyngeal Flap for Velopharyngeal Insufficiency Patients: A New Technique for Flap Inset**  
*Tarek Abdelzaher Emara, MD; Amal Saeed Quriba, MD*
- 266  **Botulinum Toxin in the Treatment of Facial Synkinesis and Hyperkinesis**  
*Roberto Filipo, MD; Irma Spahiu, MD; Edoardo Covelli, MD; Maria Nicastrì, MHS; Gian Antonio Bertoli, MD*

### GENERAL OTOLARYNGOLOGY

- 271 **Implementation of Ethics Grand Rounds in an Otolaryngology Department**  
*Andrew G. Shuman, MD; Andrew R. Barnosky, DO, MPH; Charles F. Koopmann, MD*

### HEAD AND NECK

- 275 **Randomized Controlled Trial on Postoperative Pulmonary Humidification After Total Laryngectomy: External Humidifier Versus Heat and Moisture Exchanger**  
*Jean-Claude Mérol, MD; Anne Charpiot, MD; Thibault Langagne, MD; Patrick Hémar, MD; Annemieke H. Ackerstaff, PhD; Frans J. M. Hilgers, MD, PhD*
- 282 **Microvascular Cricoid Cartilage Reconstruction With the Thoracodorsal Artery Scapular Tip Autogenous Transplant**  
*Eric J. P. Chanowski, MD, MPH; Marc J. Haxer, MA, CCC; Douglas B. Chepeha, MD, MSPH*

LK Nemocnice Č.Budějovice, a.s.



Supporting information online



Triological Society Paper



American Laryngological Association Paper



Triological Society Best Practice



- 286 ▲ Cervical Metastasis of Germ Cell Tumors: Evaluation, Management, Complications, and Outcomes  
*Saral Mehra, MD, MBA; Jeffrey Liu, MD; Amit Gupta, MD; Joel Sheinfeld, MD; Dennis Kraus, MD*
- 291 Protecting the Oral Mucosa in Patients With Oral Tongue Squamous Cell Carcinoma Treated Postoperatively With Intensity-Modulated Radiotherapy: A Randomized Study  
*Zhong-He Wang, MD; Shi-Zhou Zhang, MD; Zhi-Yuan Zhang, MD; Chen-Ping Zhang, MD; Hai-Sheng Hu, PhD; Wen-Yong Tu, MD; Jessica Kirwan, MA; William M. Mendenhall, MD*
- 299 Impact of Primary Neopharyngoplasty on Acoustic Characteristics of Alaryngeal Tracheoesophageal Voice  
*Osama A. Albirmawy, MD; Mohamed N. Elsheikh, MD; Carl E. Silver, MD, FACS; Alessandra Rinaldo, MD, FRCSEd; Alfio Ferlito, MD, FRCSEd*
- 307 Radiological Pitfalls with Laryngopharyngeal Injectables  
*Stefan W. Shuaib, BA; Andrew A. Potter, MD; Lawrence E. Ginsberg, MD; Michael E. Kupferman, MD*
- 311 A Cost-Effectiveness Analysis of Positron Emission Tomography-Computed Tomography Surveillance Versus Up-Front Neck Dissection for Management of the Neck for N2 Disease After Chemoradiotherapy  
*Amy Rabalais, MD; Rohan R. Walvekar, MD; Jonas T. Johnson, MD; Kenneth J. Smith, MD, MS*


## LARYNGOLOGY

- 315 ⓘ Patient Tolerance of Awake, In-Office Laryngeal Procedures: A Multi-Institutional Perspective  
*VyVy N. Young, MD; Libby J. Smith, DO; Lucian Sulica, MD; Priya Krishna, MD; Clark A. Rosen, MD*
- 322 Safety and Efficacy of Carboxymethylcellulose in the Treatment of Glottic Insufficiency  
*Pavan S. Mallur, MD; Michele P. Morrison, DO; Gregory N. Postma, MD; Milan R. Amin, MD; Clark A. Rosen, MD*
- 327 ⓘ Clinical Trial of Regeneration of Aged Vocal Folds With Growth Factor Therapy  
*Shigeru Hirano, MD, PhD; Ichiro Tateya, MD, PhD; Yo Kishimoto, MD; Shin-ichi Kanemaru, MD, PhD; Juichi Ito, MD, PhD*
- 332 ▲ Current Dysphonia Trends in Patients Over the Age Of 65: Is Vocal Atrophy Becoming More Prevalent?  
*Taryn Davids, MD, FRCSC; Adam M. Klein, MD, FACS; Michael M. Johns, III, MD, FRCS*
- 336 ⓘ Genetic Characterization of Vocal Fold Lesions: Leukoplakia and Carcinoma  
*Rebecca S. Bartlett, MA; W. Wesley Heckman, MD; Jason Isenberg, MD, PhD; Susan L. Thibeault, PhD; Seth H. Dailey, MD*
- 343 ⓘ Prevalence and Causes of Dysphonia in a Large Treatment-Seeking Population  
*Seth M. Cohen, MD, MPH; Jaewhan Kim, PhD; Nelson Roy, PhD, CCC-SLP; Carl Asche, PhD, MBA; Mark Courey, MD*
- 349 ▲ Potential for Promoting Recurrent Laryngeal Nerve Regeneration by Remote Delivery of Viral Gene Therapy  
*Adam D. Rubin, MD; Norman D. Hogikyan, MD; Alex Oh, Eva L. Feldman, MD, PhD*
- 356 Nonlinear Laser Scanning Microscopy of Human Vocal Folds  
*Amir K. Miri, MSc; Umakanta Tripathy, PhD; Luc Mongeau, PhD; Paul W. Wiseman, PhD*
- 364 Temporal and Spatial Expression of High-Mobility Group Box 1 in Surgically Injured Rat Vocal Folds  
*Nicole Y.K. Li, PhD; Byung-Joo Lee, MD, PhD; Susan L. Thibeault, PhD*
- 370 Position of the Hyoid and Larynx in People With Muscle Tension Dysphonia  
*Soren Y. Lowell, PhD, CCC-SLP; Richard T. Kelley, MD; Raymond H. Colton, PhD; Patrick B. Smith, DDS; Joel E. Portnoy, MD*


## OTOLOGY/NEUROTOLOGY

- 378 Magnetic Resonance Imaging Surveillance Following Vestibular Schwannoma Resection  
*Matthew L. Carlson, MD; Kathryn M. Van Abel, MD; Colin L. Driscoll, MD; Brian A. Neff, MD; Charles W. Beatty, MD; John I. Lane, MD; Marina L. Castner, RN; Christine M. Lobse, MS; Michael J. Link, MD*



- 389 **The Morphological Findings of Malleus and Incus in a Case of Marfan's Syndrome**  
*Muhammed Fatih Evcimik, MD; Fazil Emre Ozkurt, MD; Ahmet Karavus, MD; Tarik Sapci, MD*
- 393  **The Oncology of Otology**  
*Paul W. Gidley, MD; Christopher R. Thompson, MD; Dianna B. Roberts, PhD; Franco DeMonte, MD; Ehab Y. Hanna, MD*
- 401 **Association Between Bone Mineral Density And Hearing Loss in Osteogenesis Imperfecta**  
*Freya K. R. Swinnen, MS; Els M. R. De Leenbeer, MD, PhD; Stefan Goemaere, MD; Cor W. R. J. Cremers, MD, PhD; Paul J. Coucke, PhD; Ingeborg J. M. Dhooge, MD, PhD*
- 409 **Otologic Complications of Cotton Swab Use: One Institution's Experience**  
*Matthew Smith, MD; Ilaaf Darrat, MD; Michael Seidman, MD, FACS*
- 412 **Hennebert's Sign in Superior Semicircular Canal Dehiscence Syndrome: A Video Case Report**  
*Andrew G. Shuman, MD; Syed S. Rizvi, MD; Chantale W. Pirouet, AuD; Katherine D. Heidenreich, MD*

## PEDIATRICS

- 415 **Standardized Letter of Recommendation for Pediatric Fellowship Selection**  
*Jeremy D. Prager, MD; Jonathan N. Perkins, BS; Kim McFann, PhD; Charles M. Myer, III, MD; Myles L. Pensak, MD; Kenny H. Chan, MD*
- 425  **Incidence of Laryngospasm and Bronchospasm in Pediatric Adenotonsillectomy**  
*Michael I. Orestes, MD; Lina Lander, ScD; Susan Vergheze, MD; Rahul K. Shah, MD*
- 429 **Laryngeal Mask Airway Versus Endotracheal Tube in Pediatric Adenotonsillectomy**  
*David I. Sierpina, MD; Hamad Chaudhary, MD; David L. Walner, MD, FAAP; Dana Villines, MA; Karen Schneider, MD; Marissa Lowenthal, MD; Yuri Aronov, MD*

## SINONASAL

- 436 **Early Experience of Radio Frequency Coblation in the Management of Intranasal and Sinus Tumors**  
*Mohammed Iqbal Syed, MD, MRCS; Joanna Mennie, MBBS; Alun T. Williams, MD, FRCS*
- 440 **The Infusion Drain: An Approach to Treatment of Intranasal Abscesses**  
*Kristin A. Jones, MD; Ronald E. Walsh, NP; Sherard A. Tatum III, MD*
- 442 **Modified Hemi-Lothrop Procedure for Supraorbital Ethmoid Lesion Access**  
*Mark E. Friedel, MD, MPH; Shawn Li, BA; Paul D. Langer, MD, FACS; James K. Liu, MD; Jean Anderson Eloy, MD, FACS*
- 445 **Endonasal Endoscopic Exposure of the Internal Carotid Artery: An Anatomical Study**  
*Felipe S. G. Fortes, MD, PhD; Carlos D. Pinheiro-Neto, MD, PhD; Ricardo L. Carrau, MD; Rubens V. Brito, MD, PhD; Daniel M. Prevedello, MD; Luiz U. Sennes, MD, PhD*
- 452 **Endoscopic Skull Base Reconstruction of Large Dural Defects: A Systematic Review of Published Evidence**  
*Richard J. Harvey, MD; Priscilla Parmar, MD; Raymond Sacks, MD; Adam M. Zanation, MD*
- 460 **When FESS Fails: The Inflammatory Load Hypothesis in Refractory Chronic Rhinosinusitis**  
*Ahmed Bassiouni, MBBCh; Yuresh Naidoo, FRACS; Peter-John Wormald, MD*
- 467 **Microbiome Complexity and *Staphylococcus aureus* in Chronic Rhinosinusitis**  
*Leah M. Feazel, MS; Charles E. Robertson, PhD; Vijay R. Ramakrishnan, MD; Daniel N. Frank, PhD*





**SLEEP MEDICINE**

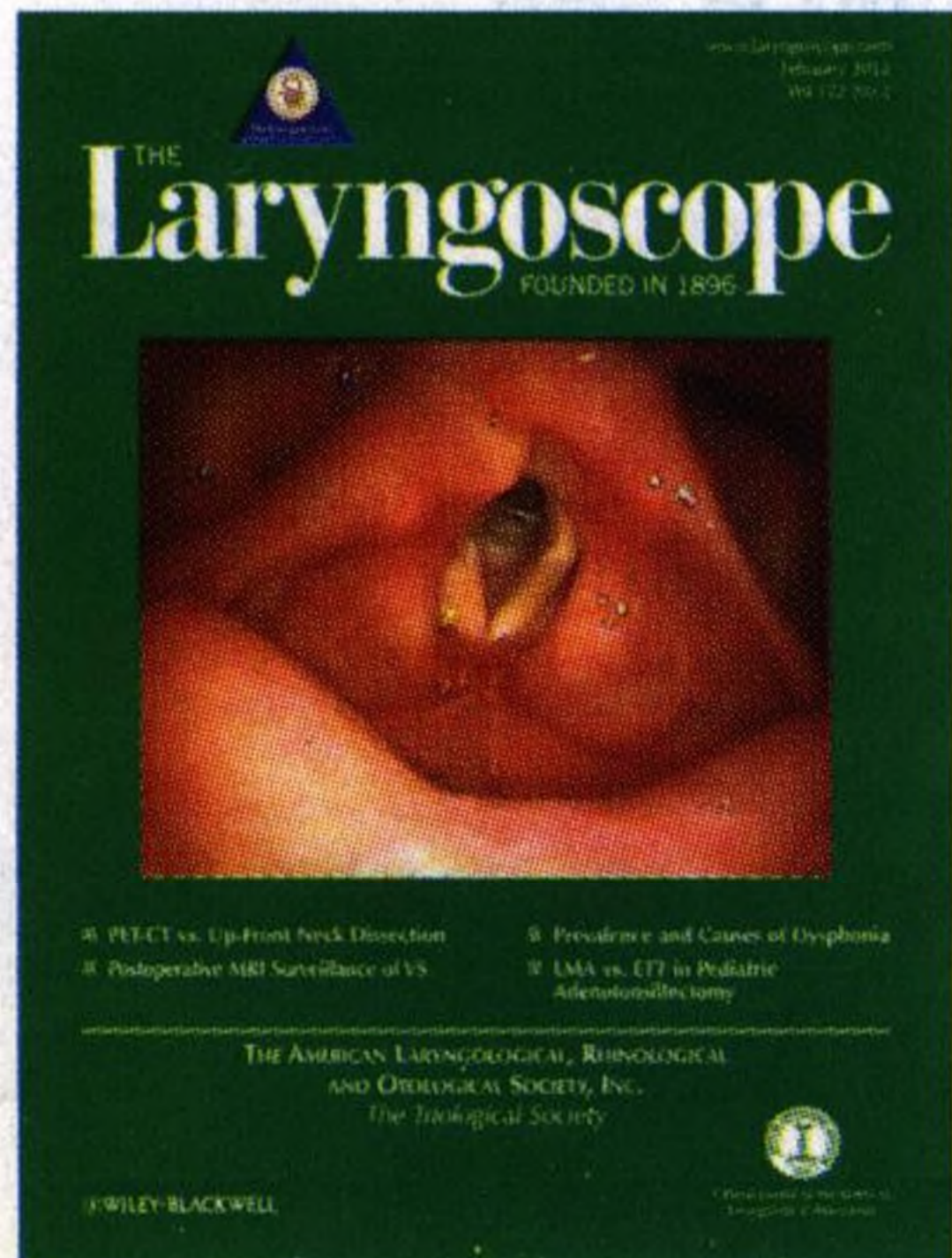
- 473 **Lateral Oropharyngeal Wall and Supraglottic Airway Collapse Associated with Failure in Sleep Apnea Surgery**  
*Danny Soares, MD; Hadeer Sinaawe, BS; Adam J. Folbe, MD; George Yoo, MD; Safwan Badr, MD; James A. Rowley, MD; Ho-Sheng Lin, MD*

**LETTERS TO THE EDITOR**

- 480 **In Reference to *Balloon Catheter Technology in Rhinology: Reviewing the Evidence***  
*Thomas A. Tami, MD; Jeffrey Cutler, MD; James Atkins, MD*
- 482 **In Response to *Balloon Catheter Technology in Rhinology: Reviewing the Evidence***  
*Pete S. Batra, MD, FACS; Matthew W. Ryan, MD; Bradley F. Marple, MD; Raj Sindwani, MD, FACS*

**LARYNGOLOGY**

- 475 **Incidence of Laryngospasm and Bronchospasm in Pediatric Anesthesiology**  
*Michael J. Oates, MD; Lisa Lander, MD; Susan Ferguson, MD; Robert K. Sisk, MD*
- 477 **Early Experience of Rapid Frequency Coughing in the Management of Intubated and Status Epilepticus**  
*Mohammed Iqbal, MD, MRCS; Joanna Mann, MRB; Mark T. Williams, MD, FRCS*
- 479 **The Intusion Drain: An Approach to Treatment of Intraoral Abscesses**  
*Kristin K. Jones, MD; Robert E. Walsh, NP; Steven A. Tatham, III, MD*
- 481 **Modified Ham-Iliostop Procedure for supraglottic Endobronchial Lesion Access**  
*Mark E. Parnis, MD, MPH; Steven L. Ba; Paul D. Cahill, MD, FRCS; Paul K. Lee, MD; Jim Harrison, MD, FRCS*
- 483 **Retrograde Endoscopic Excision of the Internal Carotid Artery: An Anatomical Study**  
*Elise S. G. Jones, MD, PhD; Curtis T. Pabst, MD, PhD; Richard F. Corbett, MD; Robert V. Bore, MD, PhD; Daniel M. Preschella, MD; Luis U. Sanna, MD, PhD*
- 485 **Endoscopic Stiff Base Reconstruction of Large Dural Defects: A Systematic Review of Published Literature**  
*Richard J. Hurry, MD; Prashila Parmar, MD; Raymond Sacks, MD; Adam M. Zeman, MD*
- 487 **When FESS Fails: The Inflammatory Load Hypothesis in Refractory Chronic Rhinosinusitis**  
*Ahmed Bahmani, MRB; Yusef Nadeem, FRCS; Peter-John Wormald, MD*



**On the Cover**

Treatment of chondrosarcoma usually involves total laryngectomy. This postoperative image is of the glottis after a one-stage resection of 60% of the cricoid cartilage and reconstruction based on the thoracodorsal artery scapular tip autogenous transplant (Tdast). The inferior aspect of the figure is the anterior surface of the larynx. The left side of the figure is the patient's right side. The mucosalized scapula tip can be seen in the subglottis on the patient's right. For further reading, please see the article on page 282 by Chanowski et al.